

Brought to You by

Gastroenterology  
& Endoscopy News

Supported by

GI Supply<sup>®</sup>  
Specialty Endoscopic Products

# Driving Patient Safety With Endoscopic Tattooing

## Faculty

**Douglas K. Rex, MD, MACP, MACG,  
FASGE, AGAF**

*Distinguished Professor of Medicine  
Indiana University School of Medicine  
Chancellor's Professor  
Indiana University Purdue University Indianapolis  
Director of Endoscopy  
Indiana University Hospital  
Indianapolis, Indiana*

## Introduction

The 1999 Institute of Medicine report found that preventable medical errors, including wrong-site surgery, caused 44,000 to 98,000 deaths each year, with an associated annual cost of \$17 billion to \$29 billion.<sup>1-3</sup> Even using the conservative estimate, this placed medical errors among the leading causes of death in the United States. Fortunately, safeguards instituted over the past decade have resulted in the reduction of preventable medical errors. This article will discuss the issue of wrong-site surgery in patients with gastrointestinal (GI) disease and the role of endoscopic tattooing in reducing this devastating error in care.

## Wrong-Site Surgery in Patients With Endoscopically Defined GI Disease

Wrong-site surgery encompasses surgery performed on the wrong side of the body, wrong surgical site, wrong surgical procedure performed, and surgery performed on the wrong patient.<sup>4</sup> Wrong-site surgery is also defined as a sentinel event (ie, an unexpected occurrence involving death or serious physical or psychological injuries, or the risk thereof) by the Joint Commission, which found wrong-site surgeries to be the third highest-ranking event among sentinel events.<sup>5</sup>

The issue of wrong-site surgery is particularly relevant to GI lesions that are identified endoscopically with subsequent referral for surgery. Indeed, the intraoperative identification of lesions previously detected by endoscopy often is difficult, particularly during laparoscopic surgery.<sup>6</sup> Estimation of the tumor site at colonoscopy can be imprecise, with as many as 14% of tumor locations incorrectly identified.<sup>7</sup> The lack of accurate lesion identification during laparoscopy may lead to resection of the wrong bowel segment.<sup>8</sup>

Wrong-site surgery is generally caused by a lack of a formal system to verify the surgical site or a breakdown of the system that verifies the correct site. The Joint Commission Center for Transforming Healthcare estimates that approximately 80% of serious medical errors, including wrong-site surgery, involve miscommunication between caregivers when patients are transferred or handed off.<sup>9</sup> This suggests that an objective system for passing information between the endoscopist and the surgeon is critical to avoid wrong-site surgery for patients with endoscopically identified lesions.

## Endoscopic Tattooing for the Prevention Of Wrong-Site Surgery

The Joint Commission recommends marking the procedure site as a prime mode of avoiding wrong-site surgery. This step serves as a durable and accurate means of communicating the location of the GI lesion between the endoscopist and the surgeon. Although traditional surgical site marking, for example during orthopedic surgery, is done by marking the surgical site on the affected limb, this avenue is obviously not applicable to marking lesions of the GI tract.<sup>10</sup>

The safety and efficacy of endoscopic tattooing has been examined in clinical studies. Whereas early endoscopic markers, such as India ink, contained impurities such as shellacs, phenols, ammonia, and animal products that could cause inflammatory reactions, modern endoscopic markers are composed of high-purity suspended carbon particles that do not have these adverse effects.<sup>11</sup> For example, Askin and colleagues studied the use of Spot (GI Supply, Camp Hill, PA) for endoscopic tattooing in 113 patients

and reported that none of the patients developed fever, abdominal pain, or signs or symptoms of inflammation.<sup>12</sup> Ten patients with colon polyps deemed endoscopically unresectable or malignant had the area surrounding the lesions tattooed and subsequently underwent surgical resection. At operation, the tattoos were visible in all cases, and none of the resected specimens exhibited necrosis or abscess formation on histopathology.<sup>12</sup> An additional 103 patients underwent colonoscopic tattooing and then underwent colonoscopy or surgery at another hospital. In the 42 patients who underwent subsequent colonoscopy 3 to 12 months after tattooing, all tattoos were readily identifiable.<sup>12</sup>

Injection of appropriately diluted and sterile marker solutions is generally safe, with most complications related to transmural injection. In a retrospective study, 195 patients were tattooed in the 4 quadrants surrounding their lesions with 0.2- to 0.5-mL marker aliquots of India ink. No short-term complications were reported. Surgeons who used endoscopic tattooing for visualization in colectomies found that the dye was helpful in identifying the area of resection during surgery.<sup>13</sup> A retrospective analysis of approximately 444 cases of colonic tattooing using various preparations found a complication in only 1 patient in whom abdominal pain, tenderness, and fever developed after tattooing a cautery-induced ulcer.<sup>14</sup>

Without proper visualization, tumors may be missed. Vignati and colleagues noted in 320 patients that 37 locations noted were incorrect, 7 cancers were missed and discovered at the time of surgery, and in 24 instances the surgeon had difficulty locating the

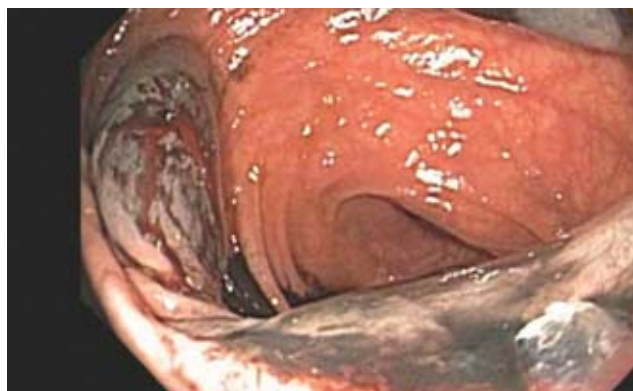
lesion.<sup>7</sup> Planned laparoscopic colorectal resection may require conversion to an open procedure in up to 14.3% of cases.<sup>15</sup> Patients who convert to open resection may experience greater blood loss, longer length of hospital stay, and a longer time to first bowel movement after surgery.<sup>16</sup>

Tattooing is valuable with rectal polyps, but in 1 series was seldom performed after resection of large and even malignant polyps. For incompletely resected polyps, tattooing made identification of the polypectomy site easier during follow-up examinations. For malignant polyps, tattooing facilitated surgical resection, whether performed by the transanal approach or by low anterior resection, and particularly for laparoscopic resections. In general, tattooing of large and potentially malignant polyps at the original endoscopic procedure prevented the need for additional endoscopy to tattoo the site for surgery when cancer was identified by the pathologist; tattooing helped to limit the extent of some resections.<sup>17</sup>

## Guidelines

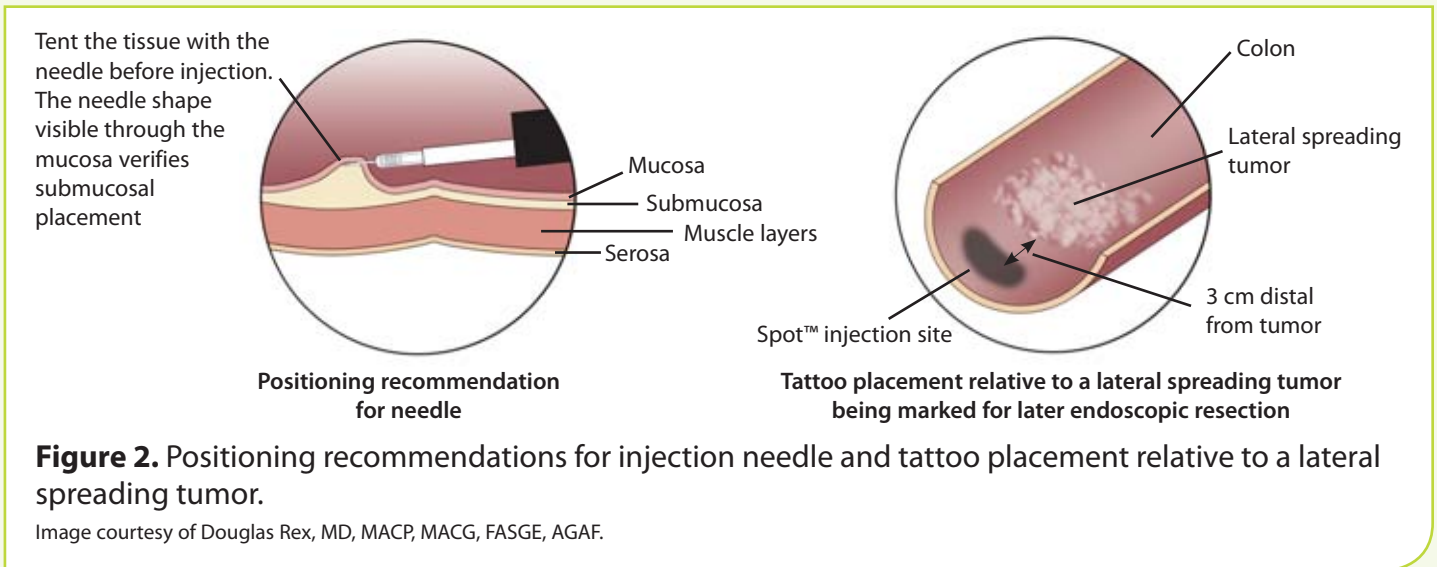
As a result of these and other studies, as well as extensive anecdotal experience, the 2014 American Society for Gastrointestinal Endoscopy (ASGE)/American College of Gastroenterology (ACG)'s quality indicators for colonoscopy suggest that "both benign and malignant lesions sent for surgical resection that are not in an area that can be identified with certainty by endoscopy (eg, the cecum and proximal ascending colon where the cecum is still endoscopically visible) and the rectum should be marked with ample submucosal injection of carbon black in 3 to 4 quadrants to ensure resection of the correct segment. If the tattoo cannot be located during surgery, intraoperative colonoscopy is needed to resolve the correct location" (Figure 1).<sup>18</sup>

Similarly, the Society of American Gastrointestinal and Endoscopic Surgeons' (SAGES) Guidelines for Laparoscopic Resection of Curable Colon and Rectal Cancer state: "When approaching colon resection laparoscopically, every effort should be made to localize the tumor preoperatively. Small lesions should be marked endoscopically with permanent tattoos before surgery to maximize the surgeon's ability to identify the lesion. Surgeons should be prepared to use colonoscopy intraoperatively if lesion localization is uncertain."<sup>19</sup> Furthermore, these guidelines state: "Tattooing is extremely important for intraoperative localization especially for small tumors or polyps and should be pursued at the time of preoperative colonoscopy. Tattooing should be accomplished using suspended carbon black, commercially prepared for this purpose. Multiple carefully placed intramural injections should be made circumferentially in the colonic wall adjacent to the lesion to maximize the surgeon's ability to localize the lesion intraoperatively."<sup>19</sup>



**Figure 1.** A 3-quadrant tattoo marking for surgery at the distal end of involvement in a patient with severe serrated polyposis.

Image courtesy of Douglas Rex, MD, MACP, MACG, FASGE, AGAF.



**Figure 2.** Positioning recommendations for injection needle and tattoo placement relative to a lateral spreading tumor.

Image courtesy of Douglas Rex, MD, MACP, MACG, FASGE, AGAF.

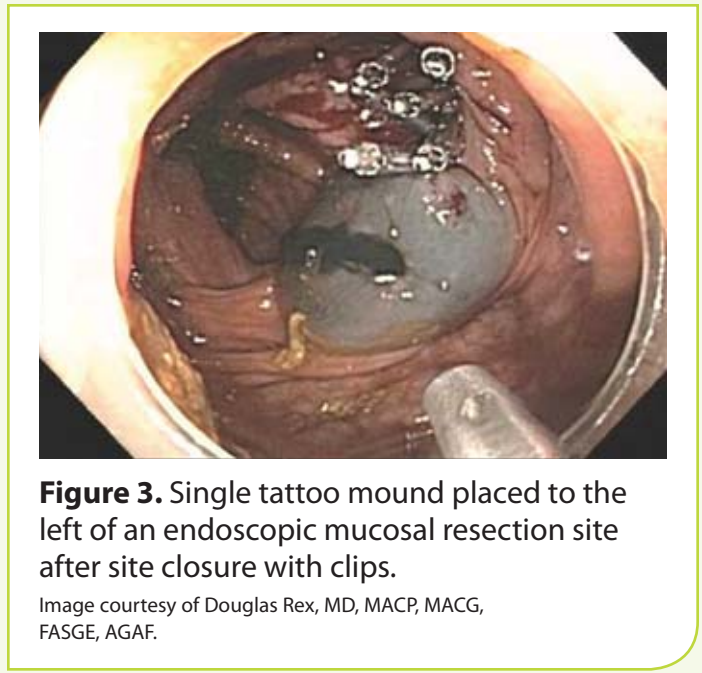Transmural injections can result in diffuse intraabdominal staining.<sup>20</sup> “If the tumor is not localized preoperatively or the pre-operative marking cannot be reliably identified during surgery, intraoperative colonoscopy should be used. When intraoperative colonoscopy is utilized, carbon dioxide insufflation may be preferable as its rapid absorption lessens the risk of a persistently distended colon interfering with surgery.”<sup>19</sup>

**Clinical Perspective**

In my practice, endoscopic tattooing is an important clinical tool. Ensuring resection of the correct segment is a joint responsibility between endoscopist and surgeon. It is important to practice appropriate techniques for tattooing; if possible, avoid injecting through the colon into the peritoneal cavity, the omentum, or another organ. The key to success is to approach the mucosa tangentially and not *en face*. Using a 23- or 25-gauge needle with a 3- to 5-mm tip, I will insert the needle into the wall and then withdraw until only one-third to half of the needle is embedded (Figure 2). Then lift toward the lumen so that the shape of the embedded needle and the location of the needle tip is visible through the mucosa. Make a small injection to confirm a submucosal bleb, and then follow with a large volume (Figure 3).

When marking a polyp for subsequent endoscopic resection, the tattoo should not be placed under the lesion. Rather, the tattoo should be placed several centimeters distal to the lesion or on the opposite wall and note the location relative to the lesion in the report. When marking an endoscopic mucosal resection site for easy location at follow-up, I will place the tattoo next to the site and into

the remaining submucosal injection mound, and note the location in the report (eg, “with the lesion down the tattoo is to the left”). When marking for surgery, the full circumference of the bowel should be marked. The location of the tattoo (eg, “a circumferential tattoo is placed 3 cm distal to the cancer”) should be noted. The endoscopist should be cautious about naming a segment with nonspecific endoscopic landmarks (eg, “the tumor is in the descending colon”).



**Figure 3.** Single tattoo mound placed to the left of an endoscopic mucosal resection site after site closure with clips.

Image courtesy of Douglas Rex, MD, MACP, MACG, FASGE, AGAF.

## Conclusion

Endoscopic tattoos are a safe and effective method for aiding in the localization of lesions throughout the GI tract and the pancreas. Endoscopists should be prepared to inject a permanent surgical marker during the initial endoscopy or colonoscopy if a lesion cannot be removed; or if an endoscopically removed polyp has clinical features that may require surgical resection or surveillance colonoscopy. Properly performed and documented endoscopic tattooing may prevent wrong-site surgery and is the standard of care to convey definitive disease localization information between the endoscopist and the surgeon.

## References

1. Institute of Medicine. <http://www.iom.edu/Reports/1999/To-Err-is-Human-Building-A-Safer-Health-System.aspx>. Accessed April 15, 2015.
2. Kohn LT, Corrigan JM, Donaldson MS. *To Err Is Human: Building a Safer Health System*. A Report of the Committee on Quality of Health Care in America, Institute of Medicine. Washington, DC: National Academies Press; 2000.
3. Thomas EJ, Studdert DM, Newhouse JP. <http://www.jstor.org/stable/29772835>. Accessed April 15, 2015.
4. AHRQ PSNet patient safety network. <http://psnet.ahrq.gov/primer.aspx?primerID=18>. Accessed April 15, 2015.
5. Joint Commission. [http://www.jointcommission.org/se\\_data\\_event\\_type\\_by\\_year/](http://www.jointcommission.org/se_data_event_type_by_year/). Accessed April 15, 2015.
6. Luigiano C, Ferrara F, Morace C, et al. *Adv Ther*. 2012; 29(10):864-873.
7. Vignati P, Welch JP, Cohen JL. *Surg Endosc*. 1994;8(9):1085-1087.
8. Wexner SD, Cohen SM, Ulrich A, et al. *Dis Colon Rectum*. 1995;38(7):723-727.
9. Joint Commission Center for Transforming Healthcare. [http://www.jointcommission.org/assets/1/18/hot\\_topics\\_transitions\\_of\\_care.pdf](http://www.jointcommission.org/assets/1/18/hot_topics_transitions_of_care.pdf). Accessed April 15, 2015.
10. Joint Commission. [http://www.jointcommission.org/assets/1/18/up\\_poster.pdf](http://www.jointcommission.org/assets/1/18/up_poster.pdf). Accessed April 15, 2015.
11. Kethu SR, Banerjee S, et al; ASGE Technology Committee. *Gastrointest Endosc*. 2010;72(4):681-685.
12. Askin MP, Wayne JD, Fiedler L, et al. *Gastrointest Endosc*. 2002;56(3):339-342.
13. McArthur CS, Roayaie S, Wayne JD. *Surg Endosc*. 1999;13(4):397-400.
14. Nizam R, Siddiqi N, Landas SK, et al. *Am J Gastroenterol*. 1996;91(19):1804-1808.
15. Moghadamyeghaneh Z, Masoomi H, Mills SD, et al. *JSLs*. 2014;18(4):e2014.00230.
16. Gonzalez R, Smith DC, Mason E, et al. *Dis Colon Rectum*. 2006;49(2):197-204.
17. Keller D, Jaffe J, Philip MM, et al. *Surg Endosc*. 2012;26(11):3101-3105.
18. Rex DK, Schoenfeld PS, Cohen J, et al. *Gastrointest Endosc*. 2015;81(1):31-53.
19. Zerey M, Hawver LM, Awad Z, et al. *Surg Endosc*. 2013;27(1):1-10.
20. Park JW, Sohn DK, Hong CW, et al. *Surg Endosc*. 2008;22(2):501-505.

Disclosure: Douglas Rex, MD, MACP, MACG, FASGE, AGAF, has received research support from Boston Scientific and Olympus. He has served on scientific advisory boards for American BioOptics, CheckCap, Colony Solutions, Epigenomics, and Given Imaging. He has received consulting fees from Boston Scientific, Endo-Aid, Ltd., Ironwood Pharmaceuticals, Olympus, and Paion AG.

Disclaimer: This article is designed to be a summary of information. While it is detailed, it is not an exhaustive clinical review. McMahon Publishing, GI Supply, and the author neither affirm or deny the accuracy of the information contained herein. No liability will be assumed for the use of the article, and the absence of typographical errors is not guaranteed. Readers are strongly urged to consult any relevant primary literature.

Copyright © 2015, McMahon Publishing, 545 West 45th Street, New York, NY 10036. Printed in the USA. All rights reserved, including the right of reproduction, in whole or in part, in any form.